

Longitudinal Striae of Human Fornix

Snezana Pavlovic, Natalija Stefanovic, Rade Cukuranovic, Svetlana Antic, Ljiljana Vasovic

Anatomy Department, Medical Faculty Nis, Yugoslavia

SUMMARY

Longitudinal striae, supracallosal fibers of fornix, were investigated in human brains. Two pairs of sagittal longitudinal striae, medial and lateral, are visible in the structure of tinny gyrus, indusium griseum (2, 13, 19). The striae make characteristic pattern on the dorsal surface of the body of corpus callosum. Although similar at first sight, the striae present some individual features which make the pattern variable.

Key words: Longitudinal striae, fornix, indusium griseum.

INTRODUCTION

Longitudinal striae are supracallosally arranged fibers of fornix, previously called fornix longus. They are projections of hippocampus, left above the callosal body after migration of the hippocampus in the early embryological stage (2). As the hippocampus itself, fornix longus is a part of the limbic system (1,2,10,12). The limbic system is seldom investigated part of the brain, and many details of its structure, projections and functions are still unknown. This is reason for very few data in the literature both about morphology and function of the limbic system. Our investigation is an attempt to elucidate some of the details of the rare described shape, relations and pattern of longitudinal striae of fornix.

MATERIAL AND METHODS

The investigation was performed on 25 adult human brains (both sexes, 20-83 years of age), without signs of visible neuropathological changes. The brains were fixed in 10% neutral formaldehyde for at least three weeks. Afterwards the cortex of the hemispheres was carefully removed, leaving corpus callosum displayed in the middle. Indusium griseum and longitudinal striae were spread upon the dorsal aspect of callosal body, between the callosal sulci. Their appearance, relations and variations were observed and presented schematically.

RESULTS AND DISCUSSION

Two pairs of distinct striae were clearly visible in the substance of indusium griseum: inner (medial) and outer (lateral).

Medial longitudinal striae were mildly undulating and run more or less next to the sagittal midline of indusium griseum. Lateral longitudinal striae were located aside, almost along the callosal sulcus, where indusium griseum continued in cingular gyrus (Fig. 1). All the striae converge anteriorly sweeping around the genu and rostrum of the corpus callosum, to merge

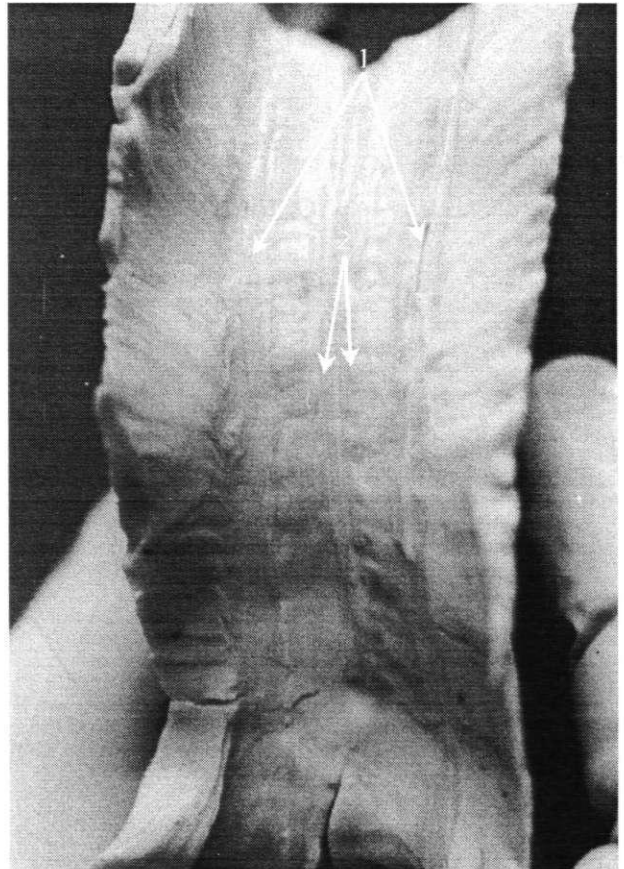


Figure 1. Indusium griseum and longitudinal striae 1. Lateral longitudinal striae 2. Medial longitudinal striae.

ge with the upper end of each paraterminal gyrus in the subcallosal area (Fig. 2). Posteriorly, all the striae diverge surrounding splenium of the corpus callosum (Fig. 3). Lateral striae continue in the fasciolar gyri and medial accompany them further anteriorly. Medial striae are more prone to variations in shape and relations.

Longitudinal striae are schematically presented on the figures 4 - 6.

Lateral longitudinal striae were single in 22 out of 25 (88%) cases, in the rest three of 25 cases (12%) they were partially duplicated. In one case both left and right lateral longitudinal striae were partially duplicated: the left in the anterior part, the right in the posterior (Fig. 6, case XXI). In the second case both left and right lateral longitudinal striae were partially duplicated in the anterior part of the striae (Fig. 6, case XXIII). In the third case both lateral longitudinal striae were also partially duplicated: left in the posterior part, right in the anterior part of the striae (Fig. 6, case XXV).

Medial longitudinal striae were individual in 18 out of 25 cases (72%). In 14 cases they were single, while

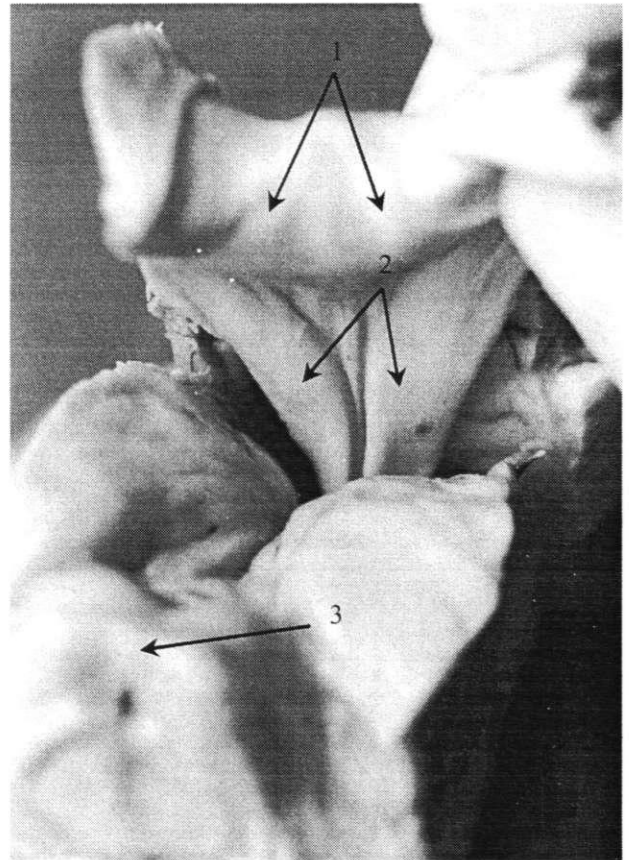


Figure 3. Outlook of the indusium griseum and longitudinal striae on the splenium of the callosal body.

1. Longitudinal striae. 2. Fasciolar gyri. 3. Quadrigeminal plate.

in the rest 4 they were partially duplicated. In two cases right longitudinal striae were partially doubled in the front parts (Fig. 6, cases IXX and XXII) and in two cases left were doubled, once in the middle part (Fig. 5, case VII) and once in the front part (Fig. 6, case XXV). In 7 of 25 cases (28%), medial longitudinal striae were partially fused or spanned in one or more places in certain lengths. In two cases medial striae were fused in two places each pair: in one case in the front and in the back part of the striae (Fig. 5, case VIII) and in the rema-

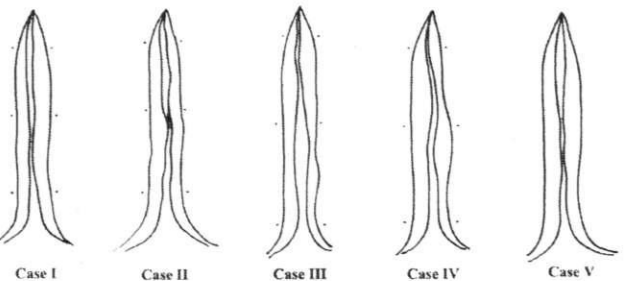


Figure 4. Schematic presentation of the longitudinal striae, cases I-V

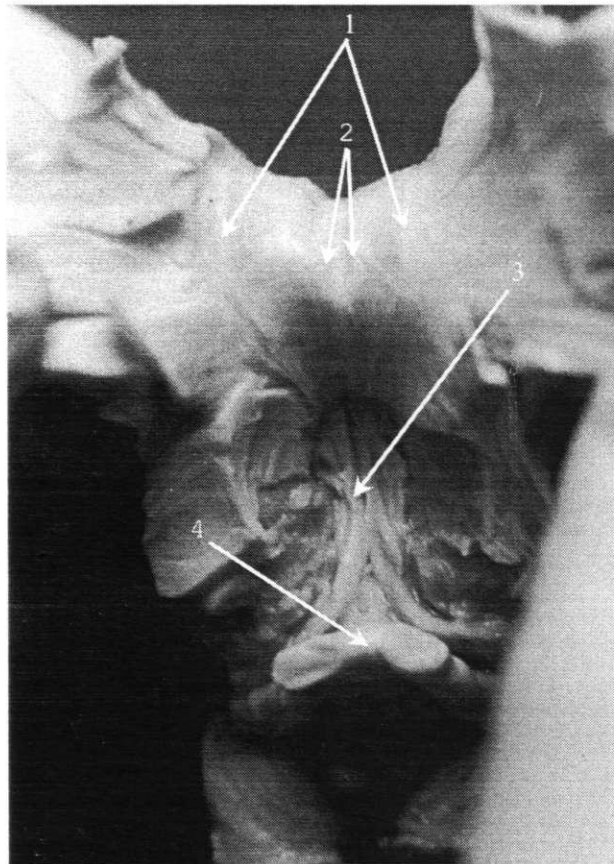


Figure 2. Outlook of the indusium griseum and longitudinal striae on the germ of the callosal body.

1. Lateral longitudinal striae. 2. Medial longitudinal striae. 3. Form. 4. Chiasma opticum.

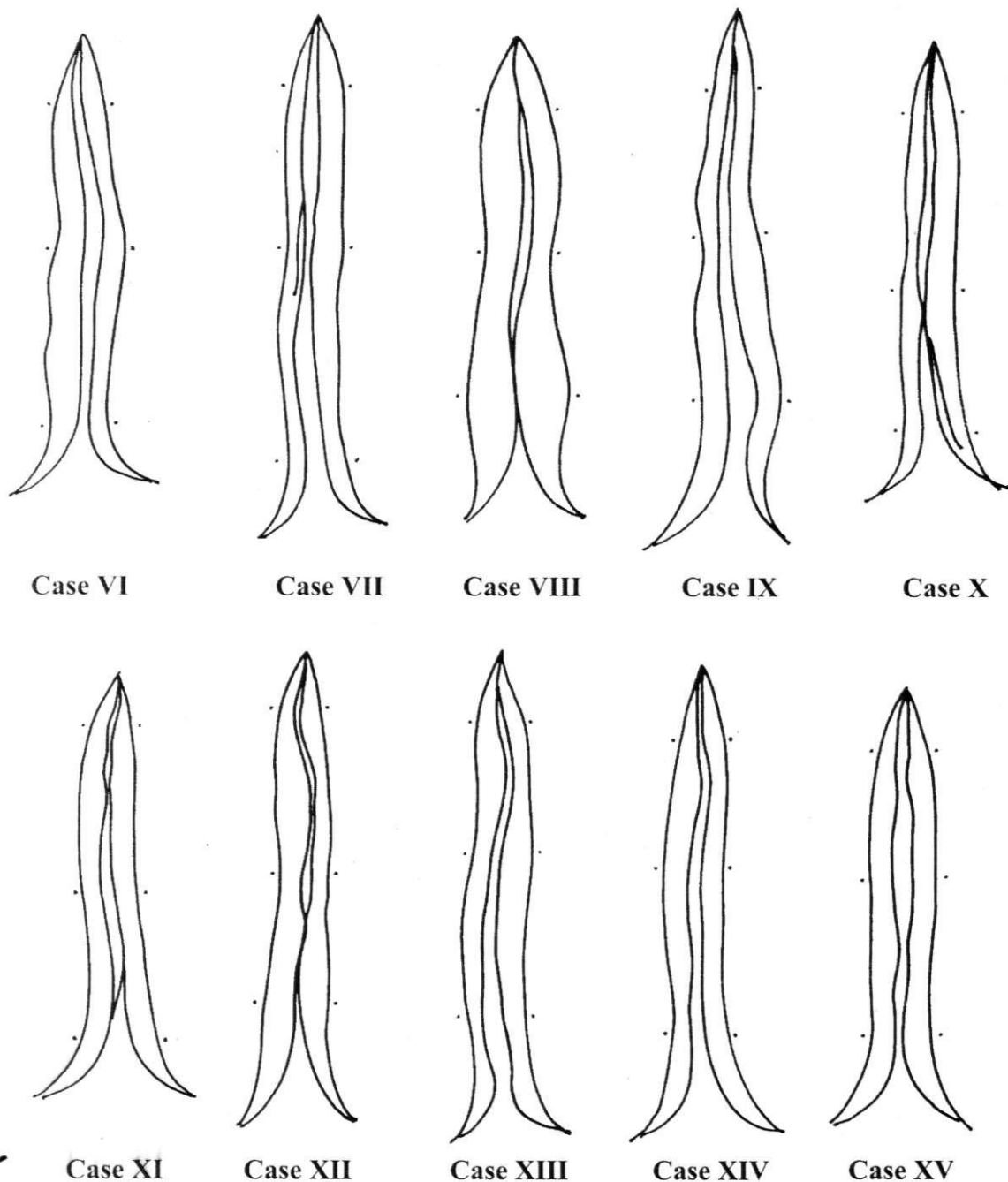


Figure 5. Schematic presentation of the longitudinal striae, cases VI-XV

in the anterior part they were fused in the front and at the back spanned with an oblique band (Fig. 5, case XI). In 5 cases medial striae were connected in one place: in two cases in the back part (Fig. 5, cases X and XII), in one case spanned with an oblique band in the front part (Fig. 4, case II), in one case the striae were spanned in the middle part with an oblique band which was part of interrupted right stria (Fig. 6, case XXI) and in one case in the front part with an oblique band which was part of

the interrupted left longitudinal stria (Fig. 6, case XXIII).

Fornix and longitudinal striae, the smaller portion of its fibers located above the corpus callosum, are the major bundle of projection fibers and constitutive part of Papez circle and limbic system in general. Since the concept of limbic system is based on functional connections the basic anatomic structures are purely defined. Some basic descriptions are present though in classical anatomy books (2, 8, 13). Unfortunately, there are not

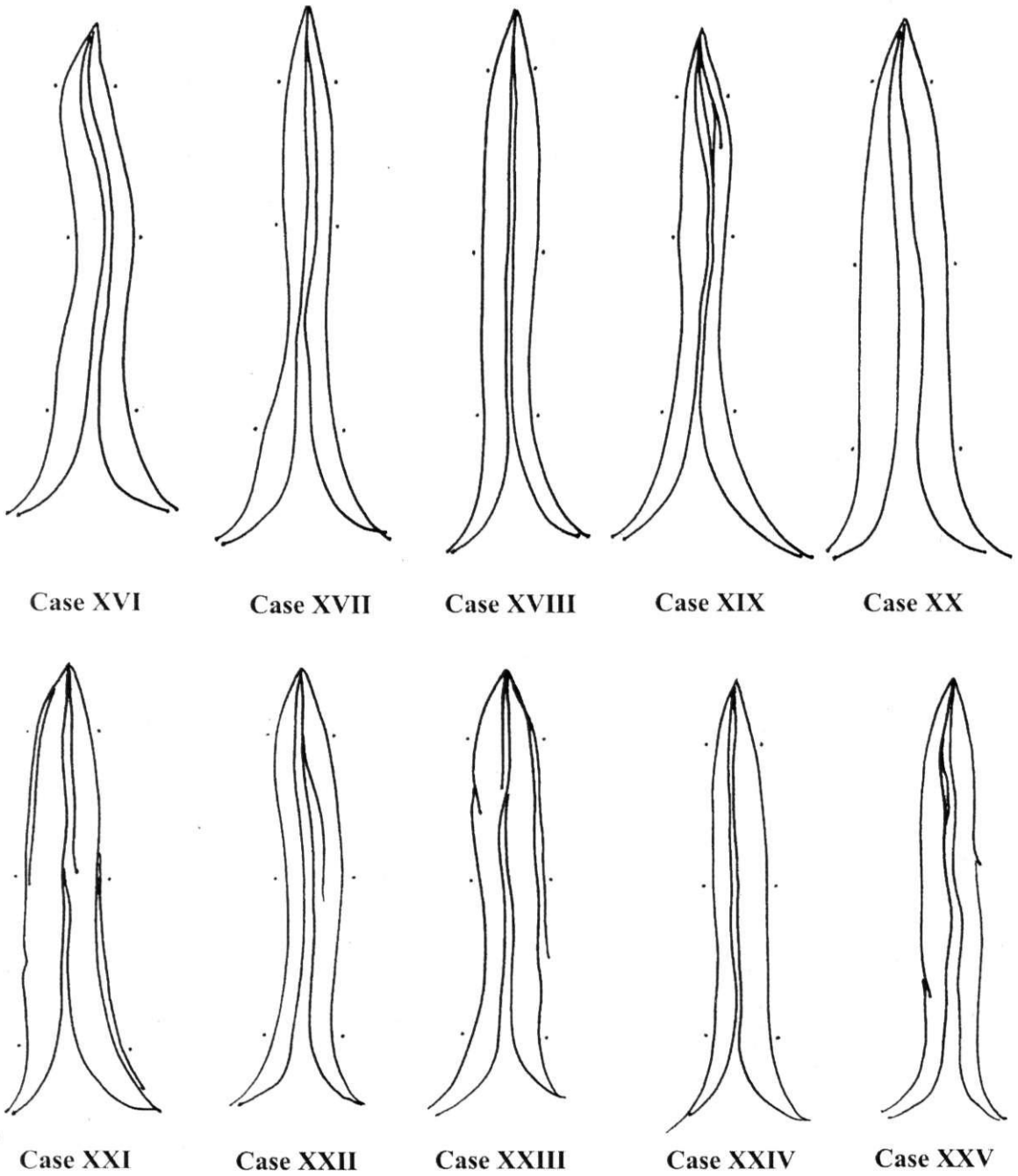


Figure 6. Schematic presentation of the longitudinal striac, cases XVI-XXV

data in the available literature about detailed structure and appearance of longitudinal striae to compare our findings with. For that reason even comparative studies in animals were of great help (1). Longitudinal striae are the most often mentioned in the embryological context, as remnant fibers of the fornix which were left on the callosal body after migration of hippocampus (10, 11, 12, 25, 28). Old anatomists, Testut and Latarjet, understood medial longitudinal striae as a vestige

and used to call them "raphe corporis callosi" (28). The relevance of longitudinal striae can't be taken separately from the fornix. It is well known that fibers of fornix provide interaction between the septal region the hippocampal formation, which appears indispensable for the maintenance of normal memory and learning mechanisms in humans. There is some evidence that dorsal route of septo-hippocampal projections, which includes longitudinal striae, have important role in

mnemonic functions (29). Immunohistochemical investigations reveal cholinergic structure of this pathway (7).

We hope that our early (23) and current attempts to describe outlook and relations of longitudinal striae as well as the shape of the pattern they create in indusium griseum, will put some light on this issue and will be of some use to further investigators of fornix and limbic system.

CONCLUSION

Individual variations in appearance and relations of longitudinal striae, which were numerous, had made basic pattern they produce in indusium griseum variable.

REFERENCES

1. ARROYO-GUIARRO J, PRATIS-GALINO A, RUANO-GIL D, COSTA-LLOBET C. Comparative study of the medial longitudinal striae of the hippocampus (formerly called "nerves of Lancisi") in the fighting bull and domestic bull. *Bulletin de l'association des anatomistes*. Mar; 72(216):15-9 1988.
2. BANNISTER LH, BERRY MM, DYSON M, DUSSEK JE, FERGLUSON MWJ. (Eds). *Gray's anatomy*. Churchill Livingstone. London, 1995.
3. BARR ML, KIERNAN JA. *The human nervous system - An anatomical viewpoint*. Harper & Row, Publishers, Philadelphia, 1982.
4. BREAK H. On the structure of the human archicortex. *Cell Tiss Res*. 1974;152:349-383
5. BREAK H, BRAAK E, YILMAZER D, BOHL J. Functional anatomy of human hippocampal formation and related structures. *J. Child. Neurol*. 11:4 265-75 1996.
6. CARPENTER M, SUTIN J. *Human Neuroanatomy*. William and Wilkins, Baltimore, 1983.
7. CHAO LP, KAN KS, HUNG FM. Immunohistochemical localisation of choline acetyltransferase in rabbit forebrain. *Brain Research*. Mar 4; 235(1):65-82 1982.
8. CHRONISTER RB, HARDY SGP. *Fundamental Neuroscience* Haines D.E. (ed) Churchill Livingstone, London, pp:443-454 1997.
9. CREUTZFELDT O.D. *Cortex Cerebri*. Springer-Verlag, Berlin, 1983.
10. DAITZ H. Note on the fibre content of the brain fornix system in man. *Brain*, 76:509-512 1953.
11. ECONOMO C. *The cytoarchitectonics of the human cerebral cortex*. Humphrey Milford Oxford University press, London, 1929.
12. DJORDJEVIC Z. Razvoj i distribucija vlakana fornickog sistema kod coveka. Doktorska disertacija. Beograd, 1972.
13. FITZGERALD MJT. *Neuroanatomy, basic and clinical*. W.B.Saunders Company LTD. London, 1997.
14. HERNANDEZ-PEON R, CHAVEZ-IBARRA G, MORGANE P.J, TIMO-IARJA C. Limbic Cholinergic Pathways Involved in Sleep and Emotional Behavior. *Experimental Neurology*. 8:93-111 1963.
15. ISAACSON R. The structure of the limbic system In: *The limbic system*. Plenum press, New York, 1982.
16. KAHLE W. Archicortex In: *Nervous system and sensory organs*. Thieme medical publishers, Stuttgart, 1993.
17. KOTTER R, MEYER N. The limbic system: a review of its empirical foundation. *Behav Brain Res* 52:105-127 1992.
18. LOPES DA SILVA FH, WATER MP, BOEIJINGA PH, LOHMAN AH. Anatomic organisation and physiology of the limbic cortex. *Physiol. Rev*. 70:2 453-511 1990.
19. MALOBABIC S, PUSKAS L, VELA A. Enlarged medial longitudinal (supracallosal) stria in one human brain. *Acta Biol. Med. Exp*. 13:87-90 1988.
20. MEGA MS, CUMMINGS JL, SALLOWAY S, MALLOY P. The limbic system: phylogenetic and clinical perspective. *J Neuropsychiatry Clin Neurosci* 9:3 315-30 1997.
21. NAUTA JWH. An experimental study of the fornix system in rat. *J. Comp. Neurol* 104:247-272 1953.
22. NAUTA JWH. Hippocampal projections and related neural pathways to the midbrain in the cat. *Brain*, 81:III; 319-340 1958.
23. PAVLOVIC S. Morfoloska, histoloska i stereoloska studija induzium grizeuma coveka. Doktorska disertacija. Nis, 1999.
24. RAKIC P, GOLDMAN-RAKIC P. Development and modifiability of the cerebral cortex. *Neurosci Res Progr Bull*. 20:429-611 1982.
25. SIDMAN RL, RAKIC P. Development of the human central nervous system. In: *Histology and histopathology of the nervous system*. W. Haymaker and R.D. Adams (eds.). C.C.Thomas (pub.). Springfield, 1982.
26. SQUIRE LR. Mechanisms of memory. *Science* 232:1612-1619 1986.
27. SWANSON LW, COWAN WM. Hippocampo-hypothalamic connections: Origin in subicular cortex, non Amon's horn. *Science*. 189:303-304 1975.
28. TESTUT L, LATARJET A. *Traite' d'anatomie humaine*. IX ed. *Angeiologie. Systeme nerveux central*. G. Doin and C'e Paris, 1948.
29. VON CRAMON DY, SCHURI U. The septo-hippocampal pathways and their relevance to human memory: a case report. *Cortex*. Sep; 28(3):411-22 1992.
30. WILLIAMS H.T, GLUHBEGOVIC N, JEWJ.Y. The human brain: dissections of the real brain. Peer review Status: Internaly Peer Reviewed. 1997.
31. ZECEVI N. Razvixce arhikorteksa. U: *Neurobiologija razvica*. Naučna knjiga, Beograd. 145-148 1990.